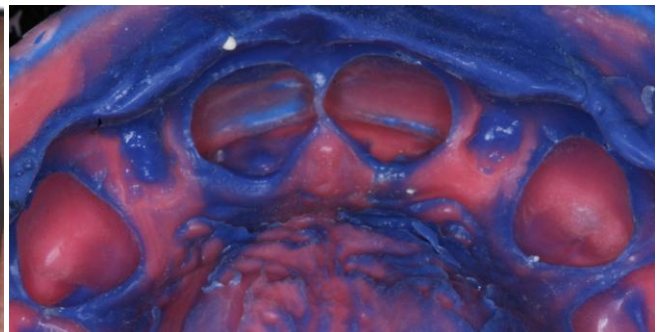
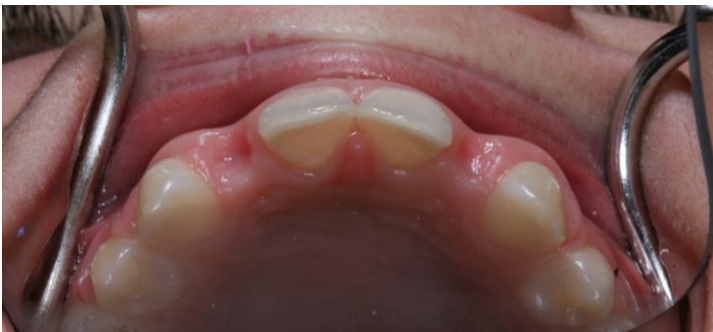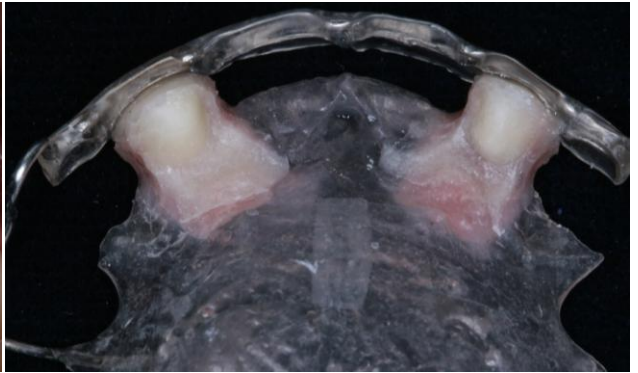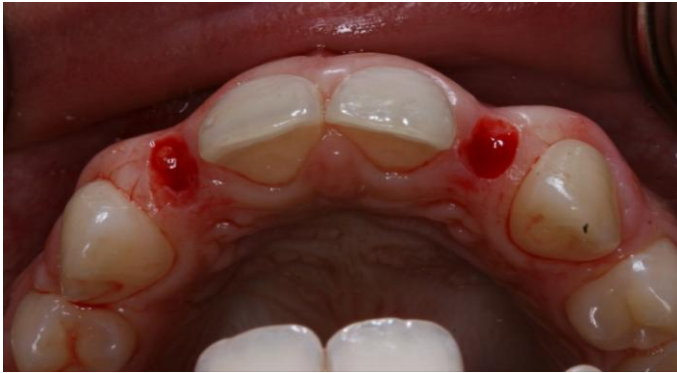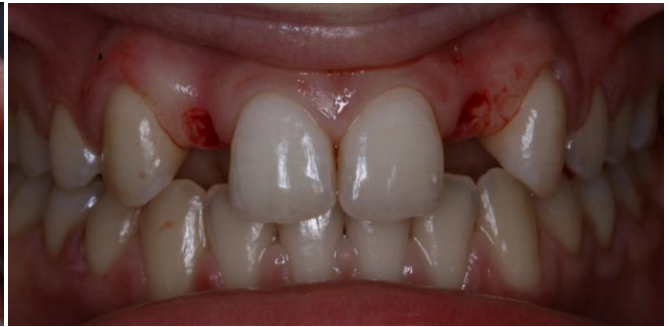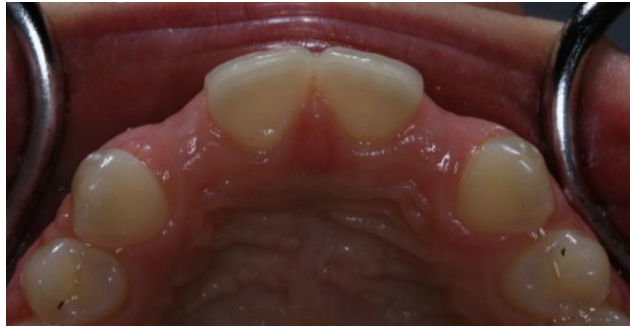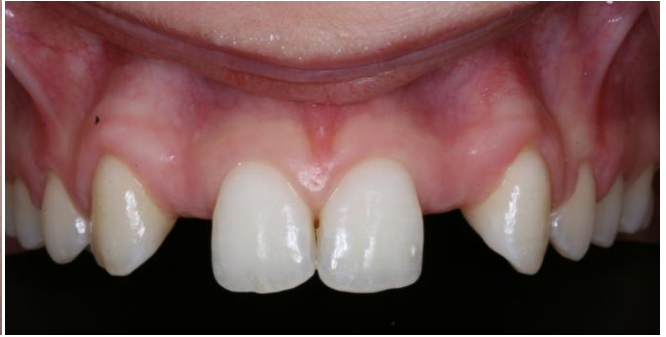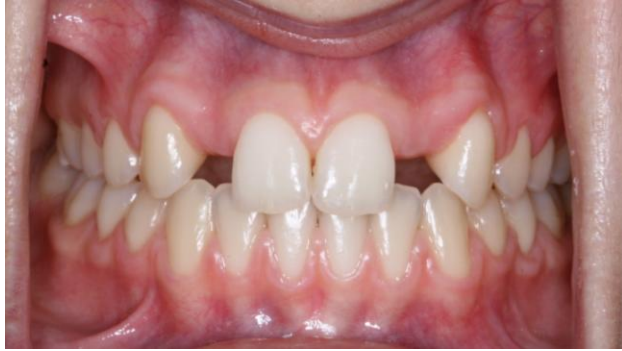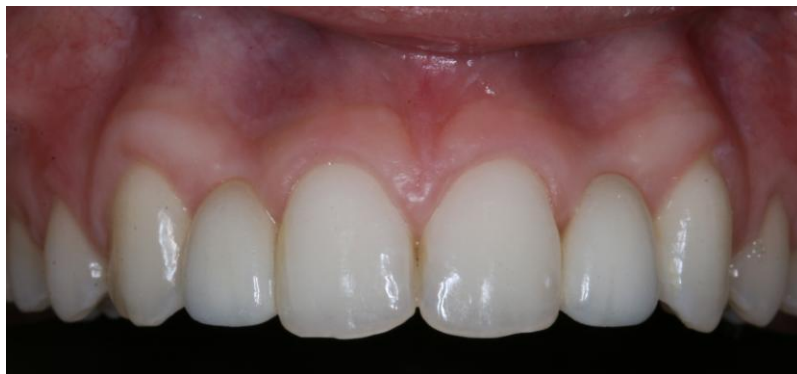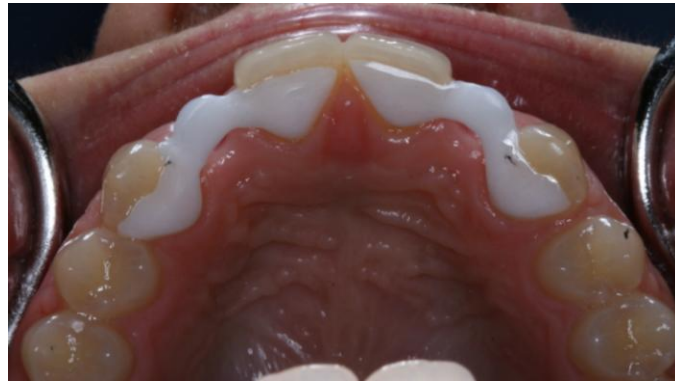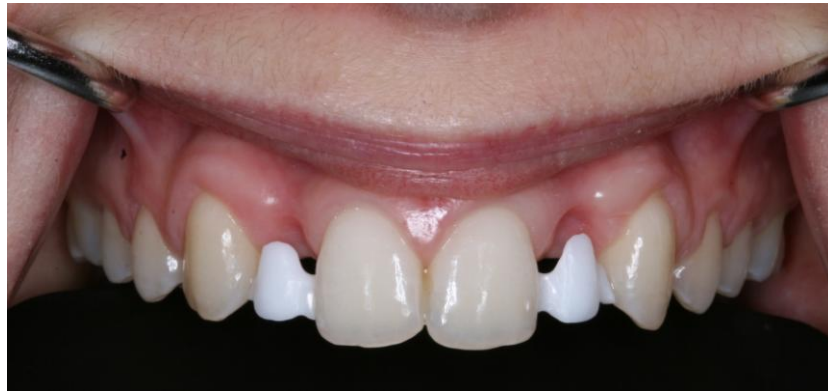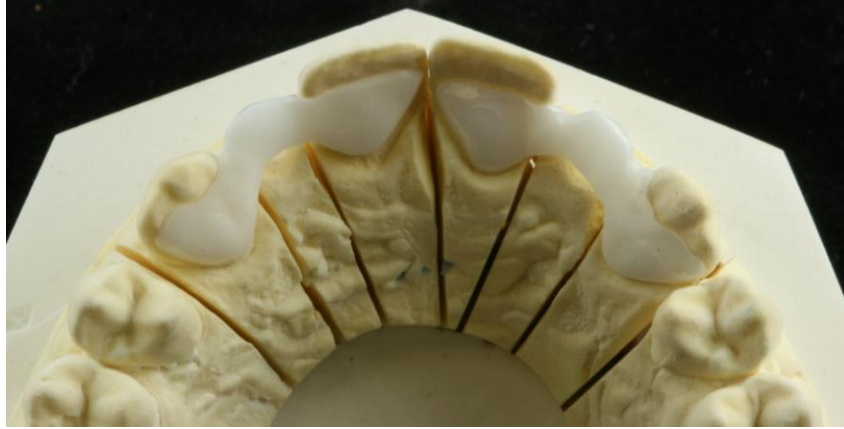


Replacing congenitally missing teeth with a bridge.





While I suggested bone grafting with implants at the site of the missing teeth, the patient's parents opted for a bridge. The cosmetic outcome is excellent, however, I believe the young patient would have been better served long-term, with grafting and implant tooth replacements.